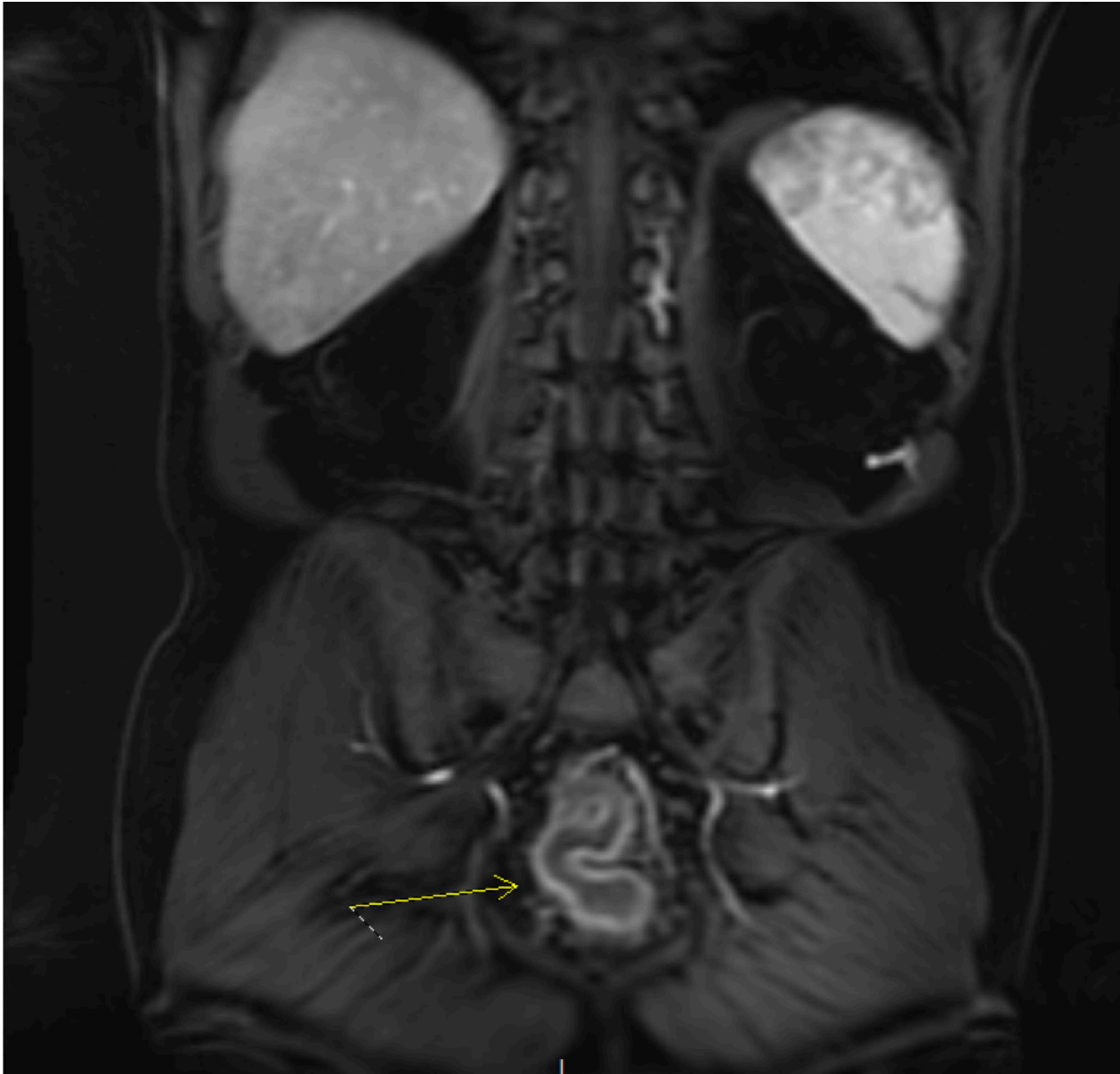


IMAGES

# MR Enterography

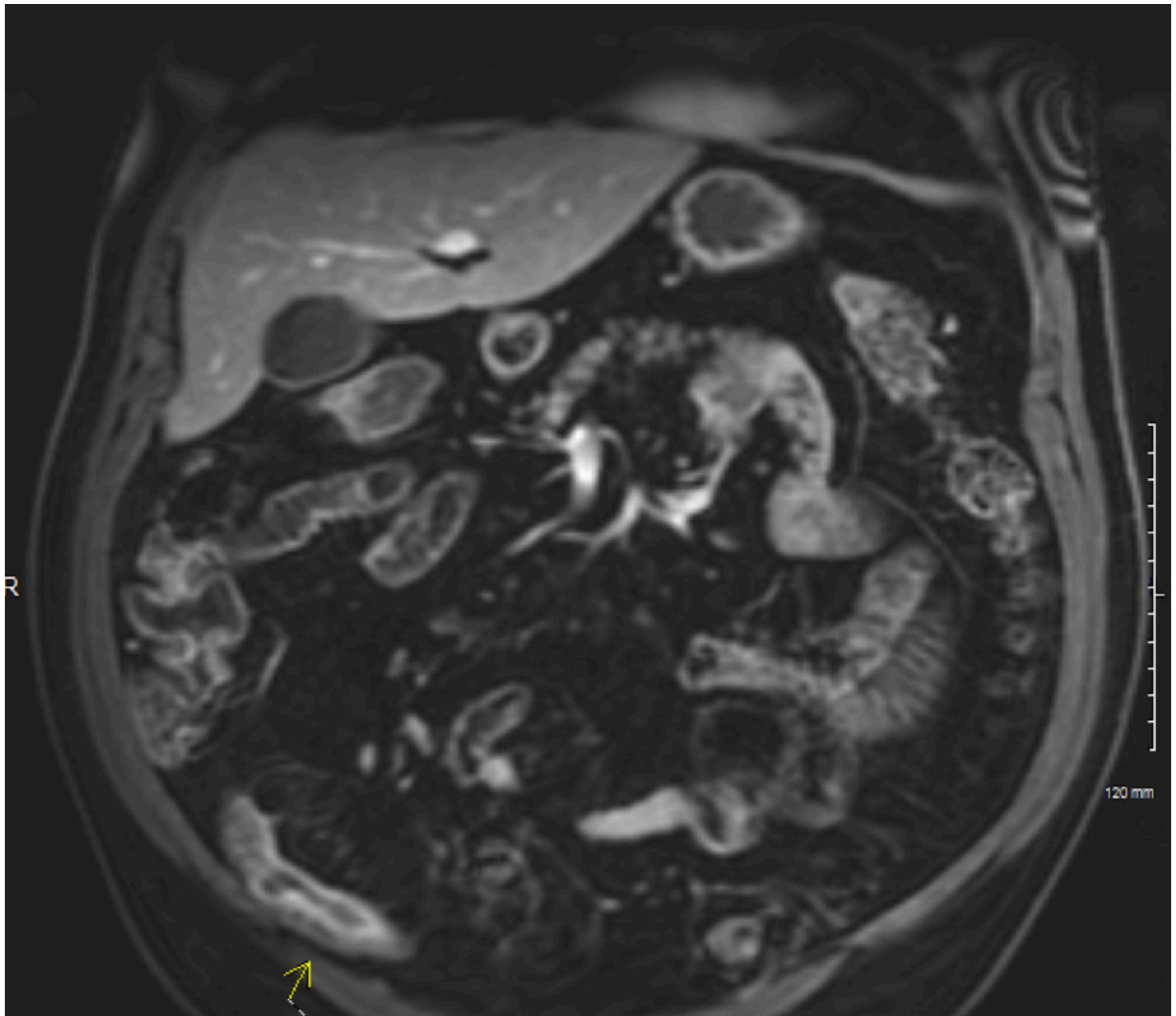
FOR CROHN'S DISEASE & COLITIS

## RECTOSIGMOID ETIOLOGY



Enhancing inflamed segment of rectosigmoid of undermined etiology.

## INFLAMMATION OF CROHN'S DISEASE



Focal active inflammation in Crohn's Disease